

ACHIEVING AESTHETIC EXCELLENCE THROUGH AN OUTCOME-BASED RESTORATIVE TREATMENT RATIONALE

Ernesto A. Lee, DMD*
Sang K. Jun, CDT†

The conceptual basis of restorative-driven implant dentistry is well established among clinicians. Its implementation includes the development of a prosthetic blueprint that will serve as a guide throughout therapy. While these concepts may be applied to prosthetic dentistry in general, their benefits are most compelling in the treatment of the aesthetic zone. This article demonstrates a systematic multidimensional approach for the establishment and incorporation of definitive aesthetic objectives throughout the diagnostic, adjunctive, and restorative treatment phases.

Key Words: outcome, waxup, blueprint, rationale

Long-term success in aesthetic dentistry is dependent on an interrelationship of several variables often not encountered in other dental disciplines. The patient's subjective interpretation of aesthetics, for example, can prove to be a significant challenge during the delivery of aesthetic treatment.¹⁻³ The role of the laboratory technician must also be taken into consideration. Aesthetic failures may occur in the laboratory, regardless of the

technician's ceramic skills, if his or her contribution is not clearly defined.^{4,5} In addition, patients who require comprehensive therapy represent a particular challenge, as they introduce yet another set of variables (ie, adjunctive procedures) that may require treatment through a multidisciplinary team approach. This article describes a rationale for aesthetic treatment planning based on the preoperative establishment of definitive restorative objectives, which often include multidisciplinary therapy. It also demonstrates a protocol for incorporating this approach throughout the various phases of clinical execution.

Preestablishing Aesthetic Objectives

Aesthetic success can be reliably predicted only through the development of a systematic, multidisciplinary treatment approach that includes the comprehensive vertical integration of a previously defined restorative outcome. This concept is not unlike the restorative-driven approach to implant therapy, which includes the initial

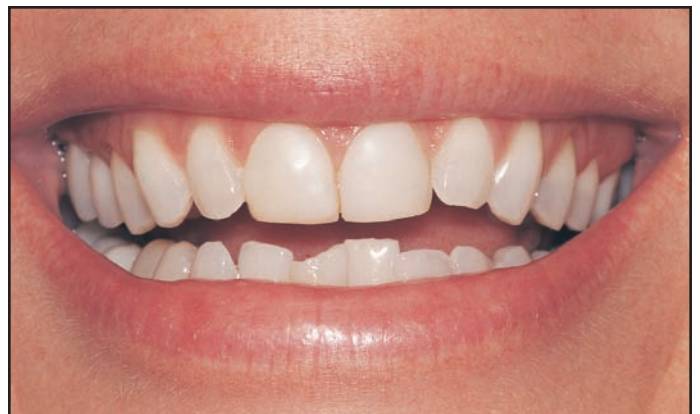

Figure 1. Case 1. Preoperative appearance of a female patient that desires conservative aesthetic solutions to address the maxillary and mandibular anterior segments.

*Clinical Assistant Professor, Postdoctoral Periodontal Prosthesis, University of Pennsylvania, Philadelphia, Pennsylvania; private practice, Bryn Mawr, Pennsylvania.

†Laboratory technician, Bay Dental Laboratory, Monterey, California.

Ernesto A. Lee, DMD
976 Railroad Avenue, Ste. 200
Bryn Mawr, PA 19010

Tel: (610) 525-1200
Fax: (610) 525-1956
E-mail: ealee@rcn.com

development of a prosthetic blueprint.^{6,7} In aesthetic dentistry, the outcome-based rationale requires an initial visualization of the desired end result, followed by a progression from abstraction to concrete clinical objectives. Therefore, the successful integration of aesthetics and functionality does not emerge by chance, but as a result of the deliberate development of clearly defined anatomical parameters and their subsequent incorporation into the design of the prosthesis.^{8,9}

The establishment of an aesthetic blueprint should be considered an integral component of the diagnostic phase. Once aesthetic objectives are defined, all adjunctive treatment considerations must be subordinated to the definitive restorative design, with the exception of measures used to control disease activity.

Techniques for Clinical Implementation

The use of computer-imaging technology has been suggested as a diagnostic adjunct in aesthetic dentistry. While it may offer a preliminary image of the anticipated results, it often does not relate specific clinical parameters to the practitioner. Although imaging technology can be a valuable practice-marketing tool and increase patient education, caution must be exercised, as it may provide an inaccurate representation of individual results and lead to unrealistic expectations and concomitant aesthetic failure.^{2,3}

The development of a diagnostic waxup is a more viable alternative to defining restorative outcomes. This

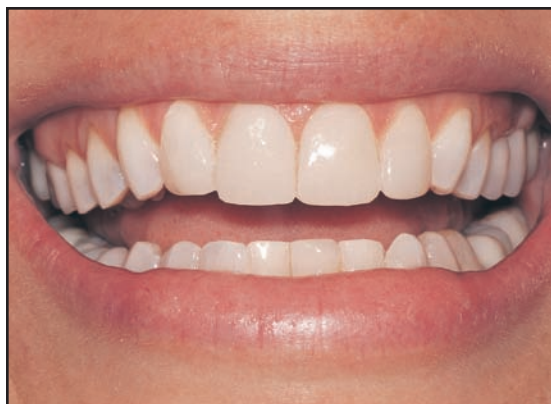

Figure 2. A proposed length increase of the maxillary incisors was evaluated with direct composite resins. The desired restorative outcome is thus preestablished and used to recruit the patient's approval.

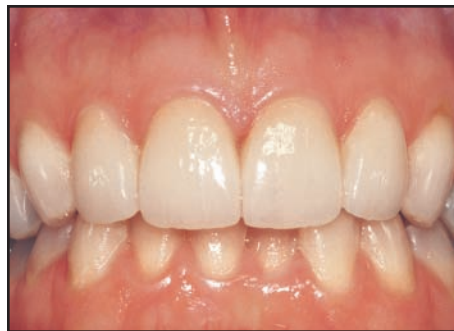

Figure 3. Postoperative view of porcelain laminate veneers on teeth #7(12) through #10(22). The results achieved demonstrate a successful integration of aesthetics and functionality.

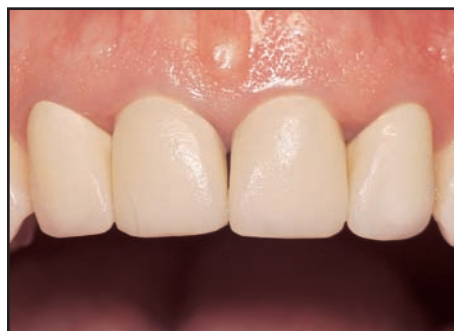

Figure 4. Case 2. Preoperative facial view. Overall aesthetic evaluation revealed the presence of short teeth relative to facial dimensions, excessive gingival display, lack of gingival harmony, and ceramic deficiencies.

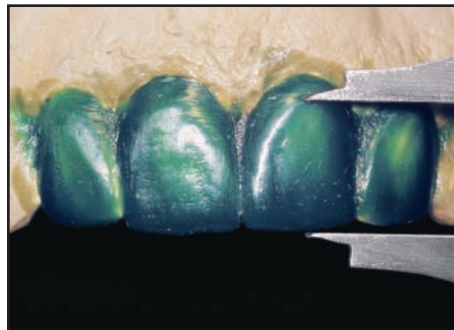


Figure 5. Diagnostic waxup incorporates a proposed increase in clinical crown length achieved through the addition of tooth structure, as well as gingival margin repositioning.

method is advantageous because it provides clinically relevant information that can be applied chairside. The waxup must be performed on study models that are precisely articulated to a previously determined occlusal vertical dimension and maxillomandibular relationship. It is critical to establish these occlusal parameters, as

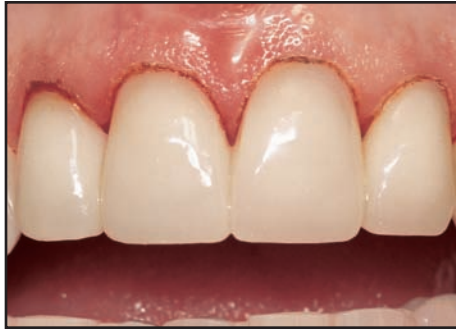

Figure 6. A provisional restoration developed from the waxup serves as a surgical template to guide electrosurgical contouring. Prior bone sounding is obligatory to preclude osseous crest exposure and injury.

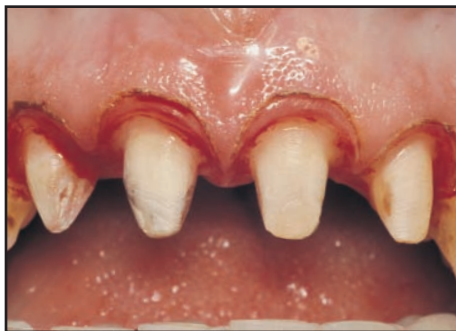

Figure 7. Facial view of tissue to be excised following electrosurgical incision. The restoration will be optimized following soft tissue healing until the predetermined aesthetic outcome has been established.

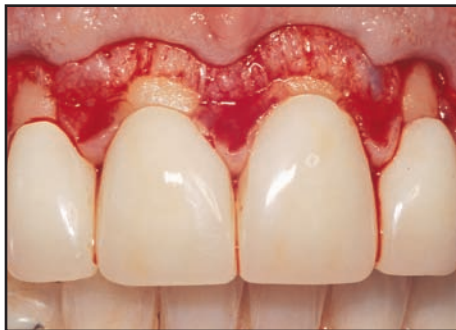

Figure 8. Osseous surgery is guided by the finalized provisional restoration to ensure adequate biologic width. Sulcular incisions are used and the papillae are preserved.

they may constitute potentially limiting functional, morphologic, and aesthetic determinants.¹⁰ The use of diagnostic occlusal appliances, a face-bow transfer, and semi-adjustable articulator is recommended whenever necessary. By incorporating accurate occlusal records as elements of the diagnostic phase, technical requirements

can be accommodated in the design of the restoration, thus avoiding compromises during its fabrication.

An essential component of the outcome-based aesthetic rationale is the utilization of techniques that allow for the intraoral evaluation of the proposed restorative blueprint. Aesthetic treatment objectives can be clinically refined and accurately represented to the patient with an intraoral evaluation of the experimental prosthesis. More importantly, this procedure allows for the clinical visualization of the definitive restorative design in a concrete format that provides the entire restorative team access to all clinically relevant information and anatomical parameters. In its simplest application, direct composite resin can be summarily placed on existing teeth for a prospective evaluation by the clinician and the patient. This approach is optimal in situations where the addition of tooth structure is being evaluated, such as an increase in the clinical crown length, mesiodistal diameter, or the facial height of contour (Figures 1 through 3).

Incorporating Aesthetic Objectives Into Multidisciplinary Treatment

Patients who require multidisciplinary therapy demand a more complex treatment planning approach. The desired aesthetic outcome must be clearly preestablished and subsequently positioned as a controlling factor throughout the various phases of treatment. The diagnostic waxup must be developed to reflect any contributory adjunctive

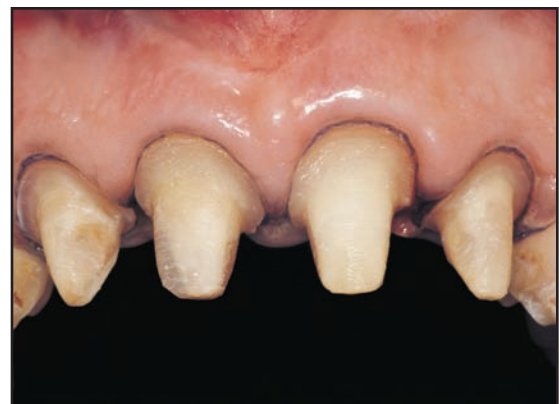

Figure 9. Following appropriate healing, the preparations are revised prior to definitive impressions. Adequate reduction must be verified with the aid of a silicon index patterned after the provisional restoration.

procedures that may be contemplated as elements of the comprehensive treatment plan, in order to establish an aesthetic restorative design in the wax stage that will most closely resemble the desired definitive result.¹¹ For example, any projected adjunctive orthodontic therapy must be executed on articulated study models prior to the diagnostic waxup, so that the latter can be accurately developed to the corrected tooth position following orthodontic movement. This not only relates invaluable diagnostic information regarding the feasibility of the expected aesthetic result, but also provides the clinician with precise orthodontic objectives.

Complex reconstructive cases that exhibit posterior bite collapse, with loss of occlusal vertical dimension and dual occlusal planes, significantly benefit from an outcome-based treatment approach. This allows the fabrication of a provisional restoration, on the maxillary arch in most instances, to an ideal occlusal plane that may subsequently serve as a guide during the orthodontic correction of the opposing mandibular segments. When dental implants are included in the treatment plan, the ability to predict the ultimate tooth position will allow accurate fixture placement prior to the orthodontic movement. This becomes a most relevant consideration in cases where the implants are to be utilized as orthodontic anchorage units.

Similarly, planned periodontal procedures (eg, gingivectomy or gingivoplasty) must be performed on the study models; the diagnostic waxup should be subsequently completed to the anticipated postsurgical gingival margin levels (Figures 4 and 5). Whenever a revision of the gingival margins is being considered, bone sounding is critical to establish the level of the osseous crest and ascertain the need for osseous surgery.^{12,13} Following bone sounding, several scenarios are possible. In ideal circumstances, sufficient tissue may be present coronal to the osseous crest to allow for a gingivectomy or gingivoplasty procedure that will establish the desired gingival margin position without violating the biologic width. A second possibility is the presence of sufficient gingival tissue to reposition the gingival margin without exposing the osseous crest, but still impinging on the biologic width. The latter situation permits the clinician to utilize

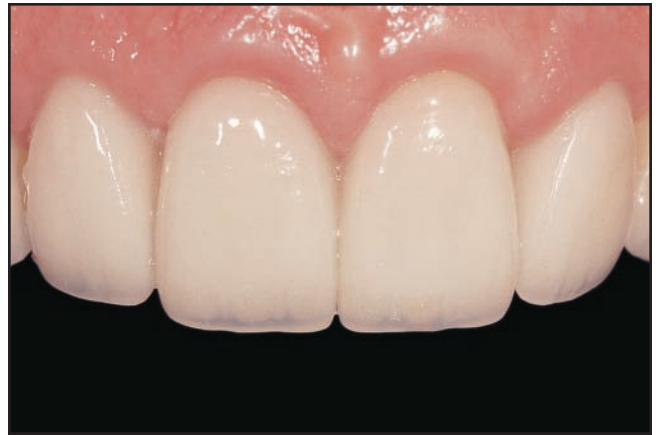

Figure 10. Postoperative facial view of the definitive pressed ceramic restorations 6 months following insertion (Laboratory: Matt Roberts).

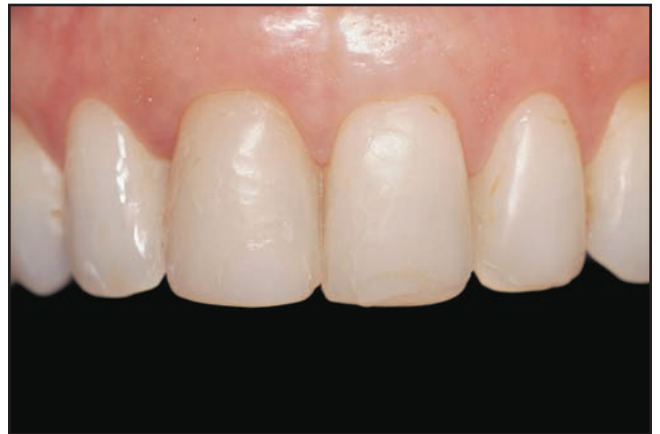

Figure 11. Case 3. Preoperative view of a 42-year-old female with multiple composite and direct veneer restorations. Tooth #5(14) was in the position of congenitally missing #6(13), and #8(11) is nonvital.

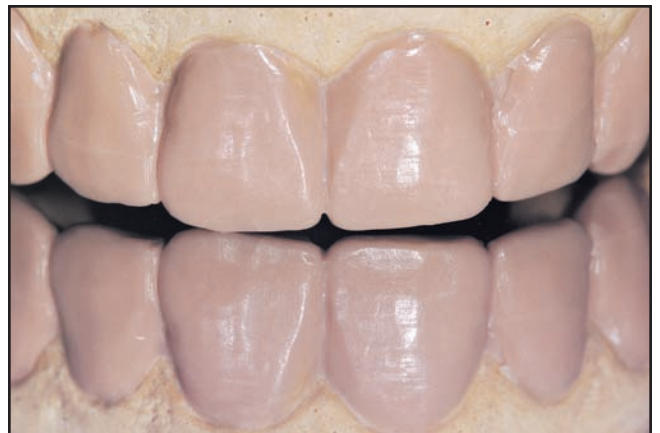

Figure 12. Diagnostic waxup attempts to improve maxillary incisor proportions while evaluating tapered anatomic forms. This is the initial phase in the development of the definitive aesthetic blueprint.

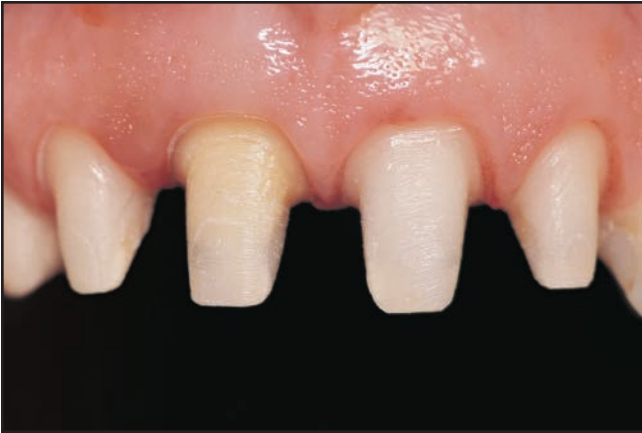

Figure 13. Facial view of outcome-based initial tooth preparations. The potential for soft tissue trauma has been minimized through careful gingival management.

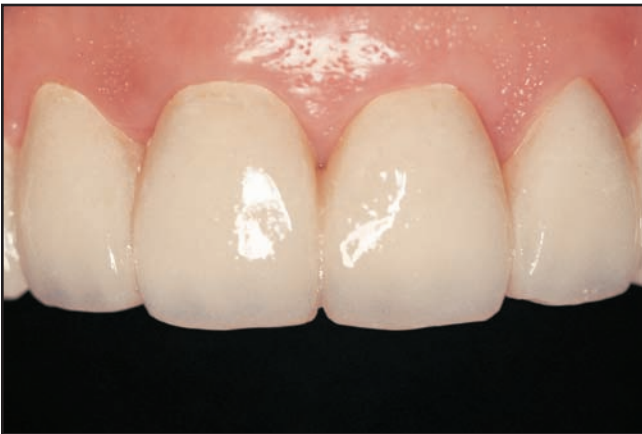

Figure 14. The provisional prosthesis is refined to fulfill the objectives desired in the final restoration. A definitive prosthetic blueprint has now been established with concrete clinical parameters.

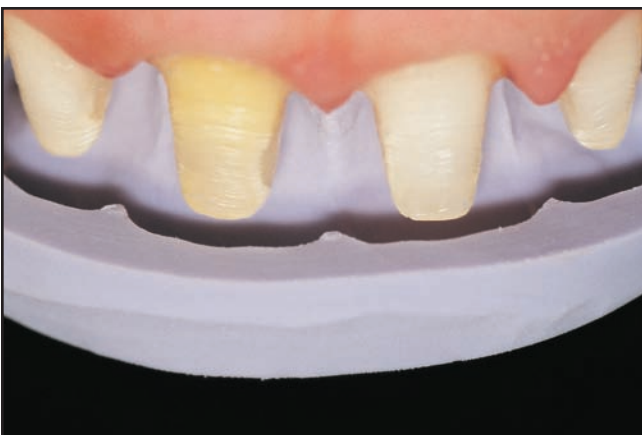

Figure 15. A silicone index patterned after the finalized provisional prosthesis ensures that the previously established restorative outcome is transferred through the various treatment phases.

the provisional restoration as a template to establish the optimal gingival margin levels. Following adequate healing, the periodontist should then be instructed to perform osseous surgery utilizing sulcular incisions and a repositioned flap approach in order to appropriately contour the osseous crest and re-establish the biologic width without altering the previously revised gingival margin levels (Figures 6 through 10).¹⁴

Bone sounding may also reveal a situation where repositioning the gingival margin to its anticipated post-treatment level will result in exposure of the osseous crest. This scenario precludes the application of any gingival revision procedures prior to surgical bone recontouring, in which case a surgical template derived from the diagnostic waxup must be provided to the periodontist. This template will serve as a guide during surgery so that following flap reflection, a constant relationship between the anticipated clinical crown and the osseous crest levels can be established and maintained through the bone-contouring process. The periodontist should also be instructed to reposition the flaps — rather than apically position them — and preserve sufficient tissue to allow for the anticipated revisions to the gingival margin levels once healing from the osseous surgery has been completed.^{15,16}

Provisional Restorations

In an outcome-based restorative approach, it is essential that the sequence of therapy be altered to incorporate the provisional prosthesis as a fundamental aspect of the diagnostic phase. The completed laboratory waxup, which reflects all planned adjunctive procedures, constitutes the basis for the fabrication of the provisional restoration. Since the aesthetic outcome is preestablished in the waxup and subsequently programmed into the design of the provisional prosthesis, the latter is utilized as a guide through adjunctive treatment procedures (Figures 11 through 14). Following intraoral placement, the provisional prosthesis is gradually modified as necessary until all the objectives required in the definitive restoration have been achieved. Once this is accomplished, the functional and aesthetic outcome has been defined in the finalized provisional prosthesis, and a blueprint is created for the design of the definitive restoration.^{17,18}

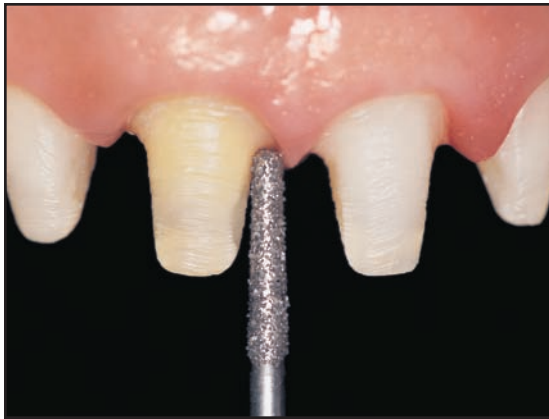


Figure 16. Final preparation guidelines must be in compliance with the specific requirements of the type of restoration selected.

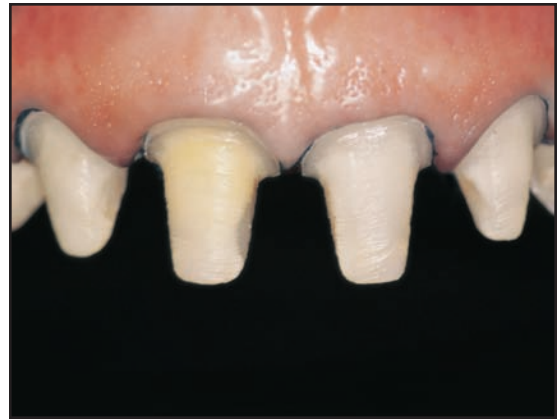

Figure 17. Facial view of cord placement and finalized tooth preparations prior to the definitive impression.

Additional measures must be used to ensure that the definitive restoration replicates the anatomic details developed in the finalized provisional restoration. To this effect, silicone indices of the provisional prosthesis are utilized as preparation guides to verify adequate tooth reduction that will provide sufficient space to accommodate the prescribed restorative materials (Figures 15 through 17).¹⁹ Tooth- and site-specific requirements must be considered in the determination of the location and type of finish line to be utilized. Finally, a category of restoration congruent with the previously established functional and aesthetic objectives must be selected.^{20,22}

Enhanced Aesthetic Outcome Prediction

Aesthetically demanding circumstances can be managed with a higher degree of predictability through the use of a sophisticated full-shade waxup technique. This technique is most useful in situations where difficult shade matching or complex individual characterizations are required. In general, the information provided by 35-mm photographs is limited by their lack of accuracy in color reproduction. Similarly, color-mapping diagrams — while beneficial — do not convey a precise dimension of degree. Without a means of intraoral evaluation and subsequent replication of the desired aesthetic outcome, definitive restorations are subject to a number of variable results, particularly when the contribution of the laboratory technician has not been clearly defined.²³

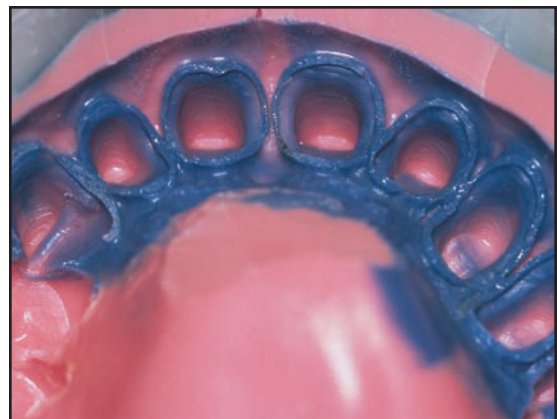


Figure 18. Definitive polyether impression of seven abutments is predictably achieved through the use of a double-cord technique.

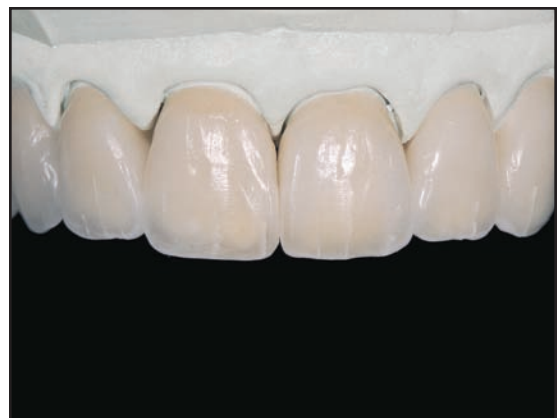

Figure 19. Full-shade waxup technique allows the incorporation of minute characterization details in aesthetically demanding circumstances.

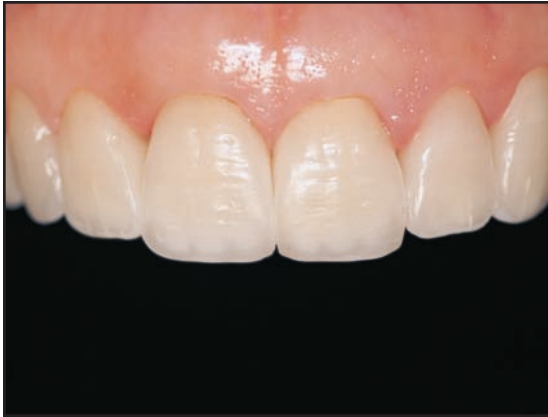

Figure 20. Wax copings allow the fully shaded wax restorations to be evaluated intraorally and modified accordingly. Individual preferences can be defined and recorded with a high degree of fidelity.

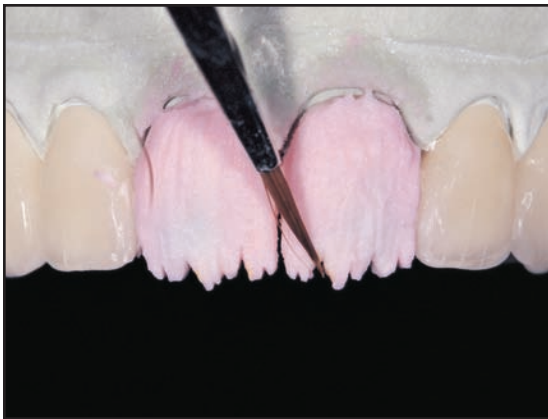

Figure 21. The full-shade waxup constitutes a superior alternative for the transfer of information to the laboratory. The role of the laboratory technician can be narrowly defined and efficiently communicated.

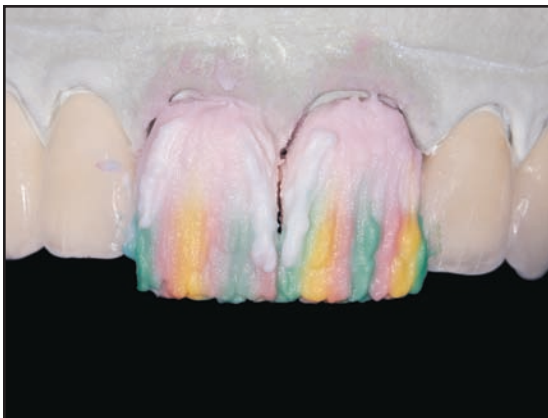

Figure 22. Complex color-mapping schemes can consequently be evaluated intraorally and successfully replicated by the laboratory technician.

The full-shade waxup technique, as previously described, is implemented following the definitive impressions (Figure 18). On a refractory model, a fully contoured waxup is developed from all relevant clinical data and will include a general shade, color-mapping schemes, and individual variables (eg, the patient's age and physiognomic characteristics). A high degree of customized aesthetic effects can be reproduced in the wax (Figure 19).²⁴

The fully contoured and shaded wax restorations are developed upon wax copings that fit intimately over the refractory dies. These wax copings possess sufficient strength and retention to allow complete seating over the actual tooth preparations. Highly specific aesthetic details (eg, enamel craze lines, incisal halos, decalcification areas, and surface textural patterns) may be incorporated in the wax. This technique allows the patient and clinician the opportunity to prospectively evaluate the in vivo appearance of the proposed restorations. More importantly, once deemed satisfactory, the laboratory technician can subsequently fabricate definitive restorations with intricate characterizations that accurately replicate the desired appearance (Figures 20 through 25).^{25,26}

The application of this technique further increases the clinician's ability to predict an aesthetic result with a higher degree of precision. By allowing intraoral evaluation, the patient's input and subsequent approval can be effectively recruited. In addition, the laboratory technician's role becomes clearly established by narrowly defining the ceramic objectives.

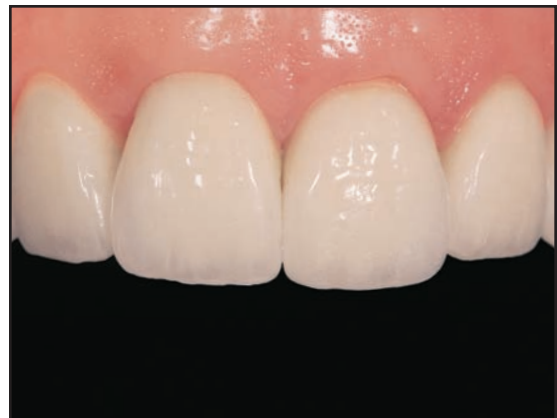

Figure 23. Postoperative facial view of the anterior maxilla displays aesthetic restorations that exhibit a harmonious and sophisticated appearance, as well as excellent soft tissue integration.

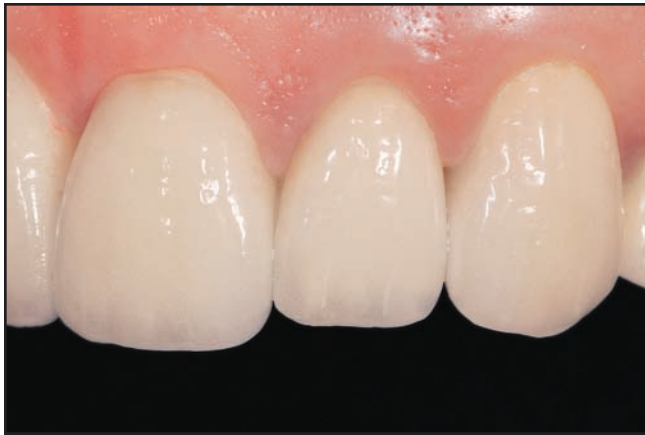

Figure 24. Left lateral view illustrates the natural appearance of the definitive restorations, which feature subtle incisal effects and surface texture details diagnosed intraorally with the shaded waxup.

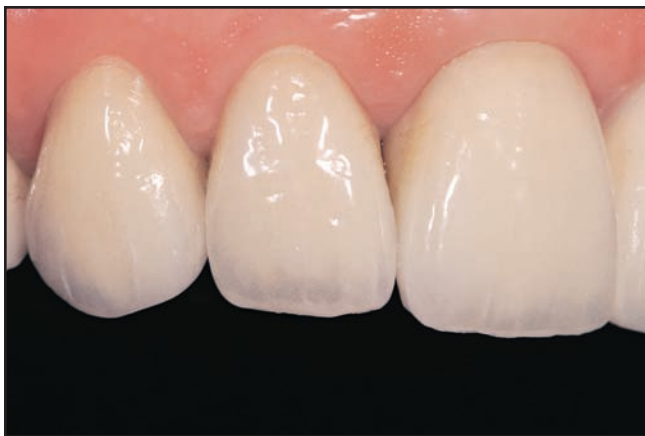

Figure 25. Postoperative right lateral view demonstrates the successful aesthetic replacement of the congenitally missing #6 by an anatomically modified #5.

Conclusion

Traditional concepts for treatment planning organize the sequence of therapy to initially address existing disease processes, followed by a corrective or restorative phase. In an outcome-based prosthetically generated treatment plan, the definitive restorative design will precede and ultimately dictate all adjunctive treatment considerations with the exception of procedures required to control active disease. This approach requires that a treatment plan be developed to support the previously defined prosthetic outcome. The clinical challenge consists of ensuring that the prosthetic blueprint is comprehensively integrated into the treatment-planning process, and transferred sequentially through the various therapeutic phases leading to completion of the case.

Acknowledgment

The authors declare no financial interests in the products featured in this article.

References

1. Rufenacht C. Fundamentals of Esthetics. Carol Stream, IL: Quintessence Publishing, 1990.
2. Chiche G, Pinault A. Esthetics of Anterior Fixed Prosthodontics. Carol Stream, IL: Quintessence Publishing, 1993.
3. Touati B, Miara P, Nathanson D. Esthetic Dentistry and Ceramic Restorations. London, UK: Martin Dunitz, 1998.
4. Miller A, Long J, Cole J, Staffanou R. Shade selection and laboratory communication. *Quint Int* 1993;24(5):305-309.
5. Muia PJ. Esthetic Restorations: Improved Dentist-Laboratory Communication. Carol Stream, IL: Quintessence Publishing, 1993.
6. Garber DA, Belser UC. Restoration-driven implant placement with restoration-generated site development. *Compend Contin Educ Dent* 1995;16(8):796-804.
7. Daftary F, Bahat O. Prosthetically formulated natural esthetics in implant prostheses. *Pract Periodont Aesthet Dent* 1994;6(9):75-83.
8. Levin EI. Dental esthetics and the golden proportion. *J Prosthet Dent* 1978;40(3):244-252.
9. Lombardi RE. The principles of visual perception and their clinical application to denture esthetics. *J Prosthet Dent* 1973;29(4):358-382.
10. Kois JC, Phillips KM. Occlusal vertical dimension: Alteration concerns. *Compend Cont Educ Dent* 1997;18(12):1169-1174.
11. Studer S, Zellweger U, Schärer P. The aesthetic guidelines of the mucogingival complex for fixed prosthodontics. *Pract Periodont Aesthet Dent* 1996;8(4):333-341.
12. Ingber JS, Rose LF, Coslet JG. The "biologic width" — A concept in periodontics and restorative dentistry. *Alpha Omegan* 1977;70(3):62-65.
13. Kois JC. Altering gingival levels: The restorative connection. Part I: Biologic variables. *J Esthet Dent* 1994;6(1):3-9.
14. Kois JC. The restorative-periodontal interface: Biological parameters. *Periodontol* 2000 1996;11:29-38.
15. Allen EP. Use of mucogingival surgical procedures to enhance esthetics. *Dent Clin North Am* 1988;32(2):307-330.
16. Lie T. Periodontal surgery for the maxillary anterior area. *Int J Periodont Rest Dent* 1992;12(1):73-81.
17. Yuodelis RA, Faucher R. Provisional restorations: An integrated approach to periodontics and restorative dentistry. *Dent Clin North Am* 1980;24(2):285-302.
18. Chiche G. Improving marginal adaptation of provisional restorations. *Quint Int* 1990;21(4):325-329.
19. Lee EA. Predictable elastomeric impressions in advanced fixed prosthodontics: A comprehensive review. *Pract Periodont Aesthet Dent* 1999;11(4):497-504.
20. Winter RR. Achieving aesthetic ceramic restorations. *J Calif Dent Assoc* 1990;18(9):21-24.
21. Ubassy G. Shape and Color. Carol Stream, IL: Quintessence Publishing, 1993.
22. Lehner CR, Mannchen R, Schärer P. Variable reduced metal support for collarless metal-ceramic crowns: A new model for strength evaluation. *Int J Prosthodont* 1995;8(4):337-345.
23. Jun SK. Shade matching and communication in conjunction with segmental porcelain buildup. *Pract Periodont Aesthet Dent* 1999;11(4):457-464.
24. Aiba N. Fabrication of custom-made ceramic restorations using Willi Geller's technique. *Quint Dent Technol* 1992;15:47-56.
25. Aoshima H. Aesthetic all-ceramic restorations: The internal live stain technique. *Pract Periodont Aesthet Dent* 1997;9(8):861-868.
26. McLaren EA. The skeleton buildup technique: A systematic approach to the three-dimensional control of shade and shape. *Pract Periodont Aesthet Dent* 1998;10(5):587-597.

CONTINUING EDUCATION (CE) EXERCISE No. 22

To submit your CE Exercise answers, please use the answer sheet found within the CE Editorial Section of this issue and complete as follows: 1) Identify the article; 2) Place an X in the appropriate box for each question of each exercise; 3) Clip answer sheet from the page and mail it to the CE Department at Montage Media Corporation. For further instructions, please refer to the CE Editorial Section.

The 10 multiple-choice questions for this Continuing Education (CE) exercise are based on the article "Achieving aesthetic excellence through an outcome-based restorative treatment rationale" by Ernesto A. Lee, DMD, and Sang K. Jun, CDT. This article is on Pages 641-648.

Learning Objectives:

This article discusses a systematic multidimensional approach for the establishment and incorporation of definitive aesthetic objectives throughout the diagnostic, adjunctive, and restorative treatment phases. Upon reading this article and completing this exercise, the reader should be able to:

- Outline the differences between traditional and outcome-based treatment planning.
- Understand how to apply an outcome-based rationale in multidisciplinary cases.

1. The achievement of successful results in aesthetic dentistry differs significantly from other dental disciplines due to the influence of the following contributory factor:

- a. Postoperative results from periodontal surgery.
- b. The role of the patient's subjective perception.
- c. Orthodontic alignment of the teeth.
- d. Adequate shade selection.

2. The following are important considerations in an outcome-based treatment approach to cases requiring multidisciplinary therapy EXCEPT for:

- a. The desired aesthetic outcome must be positioned as a controlling factor.
- b. The diagnostic waxup must reflect any contributory adjunctive procedures.
- c. Projected orthodontic therapy must be executed on articulated study models prior to the waxup.
- d. This treatment approach cannot be utilized in patients requiring endosseous implants.

3. The implementation of an outcome-based treatment rationale in aesthetic dentistry requires the following considerations EXCEPT for:

- a. Initial visualization of the desired end result.
- b. A progression from abstraction to the establishment of concrete clinical objectives.
- c. Completion of Phase I disease control procedures.
- d. Vertical integration of a preestablished restorative outcome throughout treatment.

4. In terms of sequence, the establishment of an aesthetic blueprint should be incorporated at what point in therapy?

- a. Early during the diagnostic phase.
- b. Initiated following a re-evaluation visit.
- c. Immediately prior to the clinical execution.
- d. Simultaneously with the control of active disease.

5. The fundamental requirement of an outcome-based treatment approach and use of a diagnostic waxup is:

- a. The waxup must be developed on precisely articulated study models.
- b. Models should be mounted to previously determined occlusal relationships.
- c. Splints, face-bow transfer, and semadjustable articulators must be used when necessary.
- d. All of the above.

6. Techniques that allow intraoral testing are essential to the application of an outcome-based aesthetic rationale because:

- a. Treatment objectives can be clinically refined and accurately represented to the patient.
- b. Information can be garnered regarding laboratory expenses.
- c. Multidisciplinary therapy can be coordinated more efficiently.
- d. None of the above.

7. The most important factor in ensuring successful aesthetic treatment outcomes is:

- a. Clearly defined objectives for the laboratory technician.
- b. Seamless integration of multidisciplinary therapy.
- c. Favorable aesthetic perception by the patient.
- d. All of the above.

8. Prior to considering the revision of the gingival margin levels, bone sounding is critical to:

- a. Establish the level of the osseous crest and ascertain the need for osseous surgery.
- b. Evaluate the degree of gingival inflammation.
- c. Ascertain the location of the junctional epithelium.
- d. Determine how to adjust the laser or electrosurgical unit.

9. The periodontist is instructed to reposition the flaps following osseous surgery because:

- a. It is a simpler procedure that allows faster healing.
- b. Sufficient tissue is preserved to allow anticipated gingival margin revisions following healing.
- c. There is a long-term relapse in probing depths when flaps are apically positioned anyway.
- d. A more favorable site-specific microbiota is achieved with repositioned flaps.

10. The full-shade waxup technique offers the following advantages EXCEPT for:

- a. Shaded wax copings allow prospective intraoral evaluation.
- b. Intricate effects can be evaluated in vivo and accurately reproduced in porcelain.
- c. Eliminates the need for 35-mm photographs.
- d. It is a superior laboratory communication tool and clearly defines ceramic objectives.